



Short communication

Amiodarone-induced exudative bullous lesion and hepatotoxicity in a patient with ventricular tachycardia

Ahmet Karakurt ^{a,*}, Cennet Yildiz ^b, Abdülmelik Yildiz ^c, Hamit Serdar Başbuğ ^d^a Department of Cardiology, Kafkas University Faculty of Medicine, Kars, Turkey^b Department of Cardiology, Tekden Hospital, Istanbul, Turkey^c Department of Cardiology, Asya Hospital, Istanbul, Turkey^d Department of Cardiovascular Surgery, Kafkas University Faculty of Medicine, Kars, Turkey

ARTICLE INFO

Article history:

Received 8 August 2015

Accepted 9 October 2015

Available online 18 October 2015

Keywords:

Exudative bullous lesions

Hepatotoxicity

Amiodarone side effects

ABSTRACT

Amiodarone is a potent, iodine rich, highly lipophilic class III antiarrhythmic drug widely used for the management of both supraventricular and ventricular arrhythmias. It tends to concentrate in tissues including fat, lung, liver cornea and skin. Several side effects have been reported in patients taking amiodarone. The mechanisms of amiodarone-induced side effects are poorly understood. Accumulation of amiodarone in tissues and organs has been suggested as a possible mechanism. The most frequent dermatologic side effects are photosensitivity, skin discoloration and erythema. This article presents the case of a patient who developed amiodarone-induced bullous skin lesions and hepatotoxicity.

© 2015 The Society of Cardiovascular Academy. Production and hosting by Elsevier B.V. All rights reserved. This is an open access article under the CC BY-NC-ND license (<http://creativecommons.org/licenses/by-nc-nd/4.0/>).

Introduction

Amiodarone is considered as a class III antiarrhythmic (Vaughan Williams classification). It possesses electrophysiologic characteristics of sodium, potassium and calcium channel blockage, as well as alpha and beta adrenergic blocking activity.^{1,2} It is commonly used in the treatment of supraventricular and ventricular arrhythmias, such as atrial fibrillation and ventricular tachycardia.³ It has strong antiarrhythmic properties but may cause neurologic, pulmonary, thyroid, ocular, dermatologic, and hepatic toxicity in long-term or excessive use. The mechanisms of side effects are not well understood. The most common side effects of amiodarone are nausea and vomiting, which occur in approximately 25% of patients. Side effects of the skin are also common, occurring in approximately 15% of patients.⁴ Patients frequently experience photosensitivity. Other dermatological side effects of amiodarone include skin discoloration and blue-gray or yellow-brown pigmentation. In this report, we present a case of ventricular tachycardia that developed erythematous exudative bullous skin lesions and hepatotoxicity during amiodarone therapy.

Case presentation

Sixty-one year old male patient was admitted to the emergency department with complaints of palpitation, dyspnea and chest pain. He had the same symptoms twice in the last 24 h. He denied any syncope or dizziness. He had a history of hypertension and a coronary angiography which was performed 2 years ago. The angiogram showed slow flow in the coronary arteries without any other coronary pathology. The patient was treated with acetylsalicylic acid (ASA) and antihypertensive medications.

The patient had a hemodynamically stable ventricular tachycardia. The remaining systemic examination was normal.

Electrocardiography (ECG) showed sinus rhythm in leads I–III, aVR, AVL, and AVF at initial recording. The rest of the ECG revealed monomorphic, monofocal ventricular tachycardia (VT). The rhythm on cardiac monitor was consistent with VT (Fig. A). Hemogram and biochemical parameters were within normal limits.

Two-dimensional (2-D) echocardiography was performed after medical cardioversion and cardiac measurements were determined by 2D, cross sectional M mode and Doppler study echocardiography. Echocardiographic measurements as follows: right ventricle diameter: 1.9 cm, left ventricular end-diastolic diameter: 4.5 cm, interventricular septum diastolic diameter: 1.4 cm, and the left ventricular posterior wall diastolic diameter: 1.2 cm. Left ventricular ejection fraction was calculated as 58% by using the modified Simpson technique. There was no valvular, supra- or infravalvular stenosis in the aorta and pulmonary artery.

* Corresponding author. Tel.: +90 505 2556152; fax: +90 474 2251193.

E-mail address: karakurt38@hotmail.com (A. Karakurt).

Peer review under responsibility of The Society of Cardiovascular Academy.

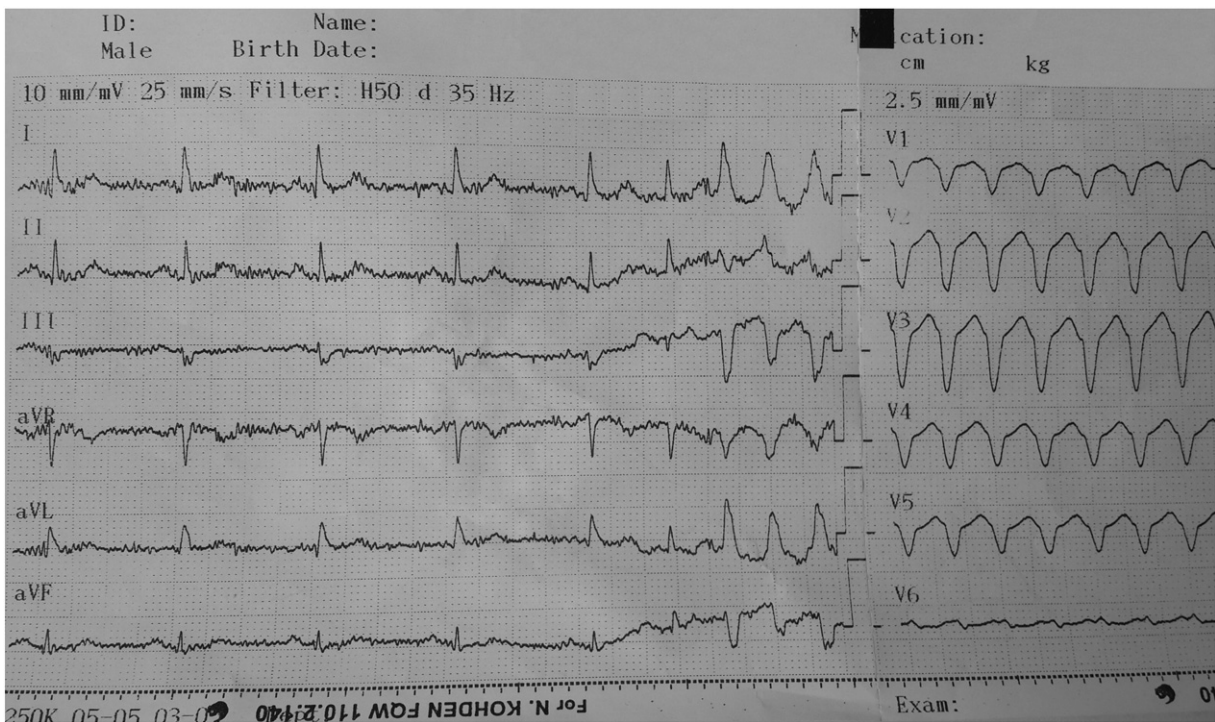


Fig. A. 12-Lead surface ECG during ventricular tachycardia.

The patient was diagnosed with sustained VT. Due to patient's stable clinical and hemodynamic parameters it was decided that a medical cardioversion was required. After loading dose of amiodarone, (150 mg in 100 mL dextrose (D5W) administered over 10 min), the patient was returned to sinus rhythm. His dyspnea and palpitations disappeared. The patient was taken to the coronary care unit and therapy was continued with a slow loading infusion containing 900 mg amiodarone injection in 500 mL of dextrose (D5W). The infusion was administered at a rate of 1 mg/min for 6 h followed by maintenance infusion at a rate of 0.5 mg/min over 18 h.

Coronary angiography revealed ectasia in the proximal and mid portions of the LAD and Cx with no critical obstructive lesions. There was also slow flow in both coronary arteries.

One day later, the patient had elevated liver enzymes and developed multiple bullous skin lesions over the anterior chest wall filled with exudative material. All bullae appeared on slightly erythematous base. Diameters of the largest and the smallest bulla were 2.3×1.5 cm and 0.6×0.7 cm respectively. Erythema was more prominent around the hair follicles and occurred both on the normal and involved skin (Figs. B and C). The biochemistry and hemogram results were as follows: Alanine transaminase (ALT) 99 U/L (normal < 41 U/L), aspartate transaminase (AST) 89 U/L (normal < 40 U/L), lactate dehydrogenase (LDH) 210 U/L (normal 135–225 U/L), monocyte 0.59 c/ μ L (normal 0.12 – 1.2 c/ μ L) and basophiles 0.08 c/ μ L (normal 0.00 – 0.02 c/ μ L). The results of other laboratory tests were within normal limits.

Amiodarone was stopped and the patient was started on propafenone (class Ic antiarrhythmic agent) orally every 12 h. During the follow-up, no VT or other arrhythmia was observed and liver enzymes returned to normal. He was discharged on the sixth day of hospitalization with prescriptions of acetylsalicylic acid 100 mg 1×1 , propafenone 150 mg 2×1 and valsartan 160 mg 1×1 . One month later, at the follow-up visit, the patient noted that his symptoms had subsided. The patient's biochemical, hemogram and ECG results were normal. Bullae healed leaving scar tissue (Fig. D).

Twenty four hour holter monitoring showed no pathological findings.

Discussion

Amiodarone is probably one of the most potent antiarrhythmic medications that we have available. Unfortunately, it also has side effects; up to 40% of patients quit amiodarone within 2 years due to those side effects.^{1,5,6} It is metabolized in the liver by cytochrome p450 enzymes and excreted in the bile. Less than 1% of the dose excreted in the urine.⁷ Its main metabolite, desethylamiodarone, has also multiple side effects.⁸ The mechanisms of side effects are not fully understood. Side effects include photosensitivity (25% to 75%), blue-gray or yellow-brown skin discoloration located mostly on the face, ears, and palms of the hands (4% to 9%), hepatotoxicity (15% to 30%); optic neuropathy/neuritis (1% to 2%), corneal microdeposits (>90%), pulmonary toxicity (1% to 17%), hypothyroidism (6%), hyperthyroidism (0.9% to 2%), tremor and ataxia (3% to 35%).³ Peripheral neuropathy, insomnia, memory loss and delirium are uncommon side effects that have been reported in the literature. Life-threatening anaphylaxis or anaphylactoid reaction, pulmonary alveolitis and fibrosis have been reported.^{2,9}

Our patient had elevated liver enzyme levels and multiple bullae. Bullae filled with no purulent fluid resembling exudates. Light microscopic skin examination revealed normal epidermis. The Hematoxylin-Eosin-Saffron stained sections demonstrated few yellow brown granules within cytoplasm of histiocytes in the mid dermis. These pigmented histiocytes clustered around capillaries. Minimal inflammation was observed. Histochemically the pigments were strongly positive by Ziehl-Neelsen, mild to moderate positive by PAS and negative by turnbull blue stainings.^{10,11}

Electron microscopy revealed polygonal to fusiform shaped histiocytes with large cytoplasm, dispersed between dermal collagen fibers. Spheroid and extended nucleolus with dense chromatin network and large cytoplasm contained dense bodies ranging in size from 250 to 2500 nm, dense granules and eosinophilic materials. No difference

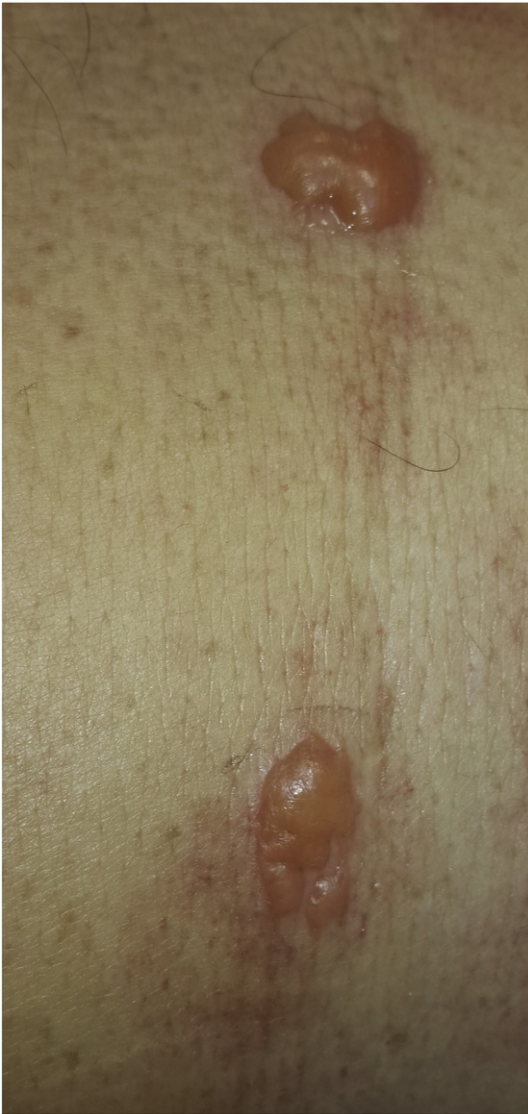

Fig. B. Multiple bullous lesions filled with material resembling exuda.

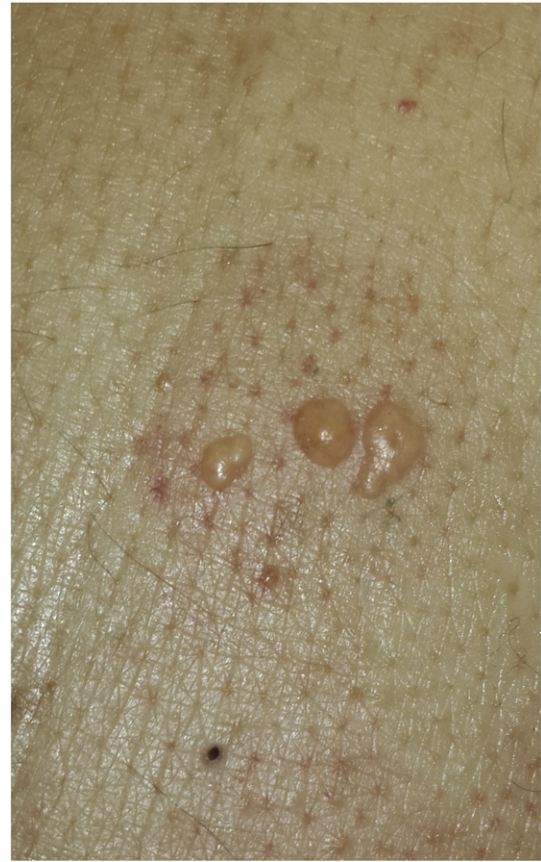

Fig. C. Multiple bullous lesions filled with material resembling exuda.

was reported in the other organelles including mitochondria, endoplasmic reticulum and free ribosomes.^{10,11}

Dermatological complications of amiodarone are time- and dose-dependent. In most cases adverse effects are reversible with discontinuation of therapy. The main skin changes induced by amiodarone are phototoxic and photoallergic reactions, as well as hyperpigmentation. More than 10% of patients have been reported to have sunlight sensitivity. The symptoms begin in several minutes after exposure to the sunlight, continue up to 24 h and usually subside in approximately 48 h, but in some cases they persist up to 72 h. Phototoxic and photoallergic reactions might even occur a few months after the withdrawal of amiodarone due to its long elimination time.¹² During long-term or high-dosage amiodarone therapy, patients should be recommended to protect themselves against photosensitivity. Patients should wear light-weight clothing that covers most surface areas of skin and use sunscreen to protect themselves from harmful UV-A/UV-B radiation.³

Blue-gray discoloration of the skin is an uncommon adverse effect caused by the accumulation of lipofuscin and melatonin in dermis.¹³ The appearance of the discoloration depends on the dosage of amiodarone and duration of use, and may regress upon cessation of the treatment.¹⁴ Biopsy confirms skin impregnation of iodine with deposition of brown pigment within dermal macrophages. Occurrence of skin

lesions does not require discontinuation of therapy. Treatment should be stopped if liver enzyme levels exceed three times the upper limit of normal.¹⁵

The amiodarone molecule contains a large amount of inorganic iodine, which may exacerbate certain skin diseases, such as dermatitis herpetiformis and psoriasis. There have been reports of post-amiodarone pseudo-purulent changes, such as acne or blister-purulent lesions characteristic of iodism.^{12,16} Less common dermatological complications of amiodarone include hives, pruritus, erythema nodosum, purpura, and the most severe variant of erythema multiforme-toxic epidermal necrolysis.^{17,18}

Amiodarone can induce allergic reactions in sensitized patients. Although the mechanisms of allergic reaction to amiodarone are poorly understood, it is believed to occur due to the 37.3% iodine that is present in the amiodarone molecule. The incidence of amiodarone induced hypersensitivity reactions in hospitalized patients with a listed allergy to iodine or iodinated contrast agents was found to be 0.4%.¹⁹ Physicians should be cautious while prescribing amiodarone for such patients.

Conclusion

Amiodarone is a potent antiarrhythmic agent that is used to treat ventricular and supraventricular arrhythmias. Side effects due to amiodarone are related to dosage and route of administration. Skin lesions are common side effects of amiodarone therapy and do not require discontinuation of treatment. Treatment should be stopped if patients develop hepatotoxicity or liver enzyme elevations greater than the triple normal limit. It should be kept in mind that exudative bullous skin lesions may occur during amiodarone therapy.

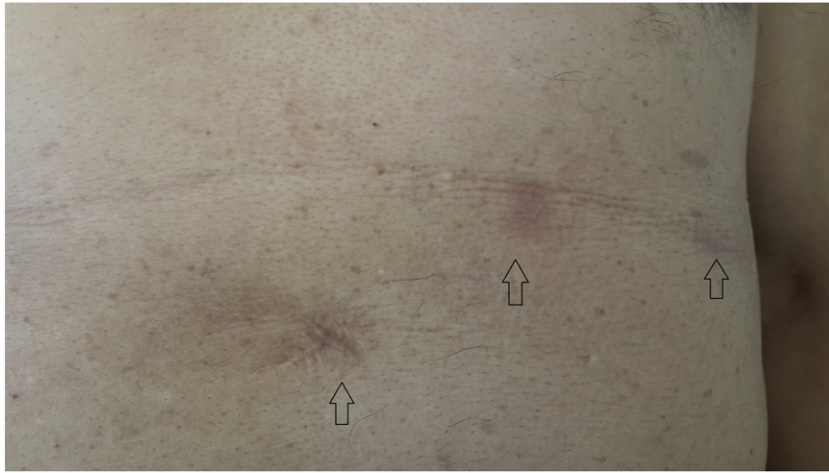


Fig. D. At one month follow-up visit, the patient showed healed bullae with scarring (black arrows).

Conflict of interest

None declared.

References

1. Aronson JK. Amiodarone. In: Dukes MNG, editor. *Meyler's Side Effects of Drugs: The International Encyclopedia of Adverse Drug Reactions and Interactions*. 15th ed. Oslo: Elsevier; 2006. p. 148–173.
2. Burches E, Garcia-Verdegay F, Ferrer M, Pelaez A. Amiodarone-induced angioedema. *Allergy* 2000;**55**:1199–2000.
3. Vassallo P, Trohman RG. Prescribing amiodarone: an evidence-based review of clinical indications. *JAMA* 2007;**298**:1312–1322.
4. Rappersberger K, Hönigsman H, Ortel B, Tanew A, Konrad K, Wolff K. Photosensitivity and hyperpigmentation in amiodarone-treated patients: incidence, time course, and recovery. *J Invest Dermatol* 1989;**93**:201–209.
5. Côté P, Bourassa MG, Delaye J, Janin A, Froment R, David P. Effects of amiodarone on cardiac and coronary hemodynamics and on myocardial metabolism in patients with coronary artery disease. *Circulation* 1979;**59**:1165–1172.
6. Razavi M. Safe and effective pharmacologic management of arrhythmias. *Tex Heart Inst J* 2005;**32**:209–211.
7. 6Latini R, Tognoni G, Kates RE. Clinical pharmacokinetics of amiodarone. *Clin Pharmacokinet* 1984;**9**:136–156.
8. Dusman RE, Stanton MS, Miles WM, Klein LS, Zipes DP, Fineberg NS, et al. Clinical features of amiodarone-induced pulmonary toxicity. *Circulation* 1990;**82**:51–59.
9. Chrysanthopoulos C, Siablis D, Kounis N. Amiodarone-induced recurrent allergic pneumonitis. *Ann Allergy* 1988;**60**:111–114.
10. Delage C, Lagacé R, Huard J. Pseudocyanotic pigmentation of the skin induced by amiodarone: a light and electron microscopic study. *Can Med Assoc J* 1975;**112**:1205–1208.
11. Zachary CB, Slater DN, Holt DW, Storey GC, MacDonald DM. The pathogenesis of amiodarone-induced pigmentation and photosensitivity. *Br J Dermatol* 1984;**110**:451–456.
12. Jaworski K, Walecka I, Rudnicka L, Gnatowski M, Kosior DA. Cutaneous adverse reactions of amiodarone. *Med Sci Monit* 2014;**20**:2369–2372.
13. Roberts M. Clinical utility and adverse effects of amiodarone therapy. *AACN Adv Crit Care* 2010;**21**:333–338.
14. Siddoway LA. Amiodarone: guidelines for use and monitoring. *Am Fam Physician* 2003;**68**:2189–2196.
15. Harris L, McKenna WJ, Rowland E, Holt DW, Storey GCA, Krikler DM. Side effects of long-term amiodarone therapy. *Circulation* 1983;**67**:45–51.
16. Abel EA, DiCicco LM, Orenberg EK, et al. Drugs in exacerbation of psoriasis. *J Am Acad Dermatol* 1986;**15**:1007–1022.
17. Bencini PL, Crosti C, Sala F, et al. Toxic epidermal necrolysis and amiodarone treatment. *Arch Dermatol* 1985;**121**:838.
18. Yung A, Agnew K, Snow J, Oliver F. Two unusual cases of toxic epidermal necrolysis. *Australas J Dermatol* 2002;**43**:35–38.
19. Lakshmanadoss U, Lindsley J, Glick D, Twilley CH, Lewin 3rd JJ, Marine JE. Incidence of amiodarone hypersensitivity in patients with previous allergy to iodine or iodinated contrast agents. *Pharmacotherapy* 2012;**32**:618–622.