CASE REPORT

DOI: 10.4274/ijca.2026.41275
Int J Cardiovasc Acad 2026;12(3):170-173

Primary Brock Procedure for Pulmonary Atresia with Intact Ventricular Septum in a Neonate: A Case Report from a Resource-limited Cardiac Center

Beni Indra[1], Ardiansyah[2], Yose Wizano[3], Aldy Heriwardito[1]

[1]Division of Cardiovascular, Department of Anesthesiology, University of Indonesia Faculty of Medicine; RSUPN Dr. Cipto Mangunkusumo, Jakarta, Indonesia
[2]Division of Cardiothoracic and Vascular Surgery, University of Andalas Faculty of Medicine; RSUP Dr. M. Djamil, Padang, Indonesia
[3]Division of Cardiovascular, Department of Anesthesiology, University of Andalas Faculty of Medicine; RSUP Dr. M. Djamil, Padang, Indonesia

Abstract

Pulmonary atresia with intact ventricular septum (PA-IVS) is a rare cyanotic congenital heart disease characterized by unstable neonatal physiology and considerable perioperative complexity. We report the case of an 8-day-old male neonate with PA-IVS who presented with fluctuating oxygen saturation despite receiving prostaglandin E1 infusion. Alternative strategies include transcatheter pulmonary valvuloplasty and a systemic-to-pulmonary shunt. However, primary surgical pulmonary valvotomy was selected in this case, given the favorable right ventricular (RV) growth potential and the physiological imperative to establish antegrade pulmonary blood flow while avoiding shunt-dependent circulation. Perioperative management emphasized preserving RV preload, maintaining systemic vascular resistance, and maintaining balanced pulmonary-to-systemic blood flow. Intraoperative reassessment supported the chosen surgical strategy. The patient achieved sustained hemodynamic stability and progressive improvement in oxygenation throughout the postoperative period. This case underscores the critical role of multidisciplinary decision-making in determining the optimal palliation strategy for PA-IVS, particularly in centers with limited access to advanced congenital cardiac services.

Keywords: Pulmonary atresia with intact ventricular septum, Brock procedure, duct-dependent circulation, perioperative management, resource-limited setting

INTRODUCTION

Pulmonary atresia with intact ventricular septum (PA-IVS) is a rare cyanotic congenital heart defect characterized by right ventricular (RV) outflow tract obstruction, with survival dependent on preserved RV function and a balanced pulmonary-to-systemic blood flow ratio (Qp:Qs).[1,2]

Early palliation is required to maintain pulmonary perfusion. Contemporary management options include transcatheter valvuloplasty or a modified Blalock-Taussig (BT) shunt. In selected neonates with favorable RV morphology, surgical valvotomy using the Brock procedure may restore antegrade flow without cardiopulmonary bypass (CPB).[3] This report describes the perioperative management of a neonate with PA-IVS undergoing the Brock procedure at a center with limited resources.

To cite this article: Indra B, A, Wizano Y, Heriwardito A. Primary Brock procedure for pulmonary atresia with intact ventricular septum in a neonate: a case report from a resource-limited cardiac center. Int J Cardiovasc Acad. 2026;12(3):170-173

Address for Correspondence: Beni Indra MD, Division of Cardiovascular, Department of Anesthesiology, University of Indonesia Faculty of Medicine; RSUPN Dr. Cipto Mangunkusumo, Jakarta, Indonesia
E-mail: drbeniindra@gmail.com
ORCID ID: orcid.org/0000-0002-4615-0018

Received: 07.03.2026
Accepted: 02.07.2026
Epub: 20.07.2026
Publication Date: 29.09.2026

©Copyright 2026 Author(s). Published by Galenos Publishing House on behalf of the Cardiovascular Academy Society.
Licensed by Creative Commons Attribution-NonCommercial-NoDerivatives 4.0 (CC BY-NC-ND 4.0)

CASE REPORT

An 8-day-old male neonate with a birth weight of 2600 g, born at 35-36 weeks of gestation (Apgar 7/8), was referred for early respiratory distress and persistent hypoxemia. Initial management included continuous positive airway pressure (CPAP).

Physical examination revealed peripheral cyanosis. Respiratory rate was 45-55 breaths/min, oxygen saturation fluctuated between 50-85%, and there was a significant pre- and post-ductal gradient (64% vs. 51%). Heart rate was 135-145 beats/min, S1S2 were normal, and a cardiac murmur was present.

Arterial blood gas showed severe hypoxemia with mild metabolic acidosis (pH 7.31, PaO_2 31 mmHg, HCO_3 18.6 mmol/L). Given the marked desaturation and a ductal gradient, a duct-dependent congenital heart defect was suspected. Echocardiography identified PA-IVS, a 6-7 mm secundum atrial septal defect (ASD) with bidirectional shunt, patent ductus arteriosus (PDA), along with hypoplastic pulmonary arteries, and moderate tricuspid regurgitation. Further assessment demonstrated a tripartite RV with preserved inlet, trabecular, and outlet components; the ventricles appeared relatively balanced, without severe RV hypoplasia. The tricuspid annulus measured approximately 13 mm, which is within the normal range for age. Although a formal tricuspid valve Z-score was not available, the echocardiographic findings supported the feasibility of a biventricular repair pathway. The absence of a Z-score is acknowledged as a limitation of this assessment (Figure 1). The neonate was admitted to the neonatal intensive care unit (NICU) and was started on a prostaglandin E1 (PGE1) infusion to maintain ductal patency.

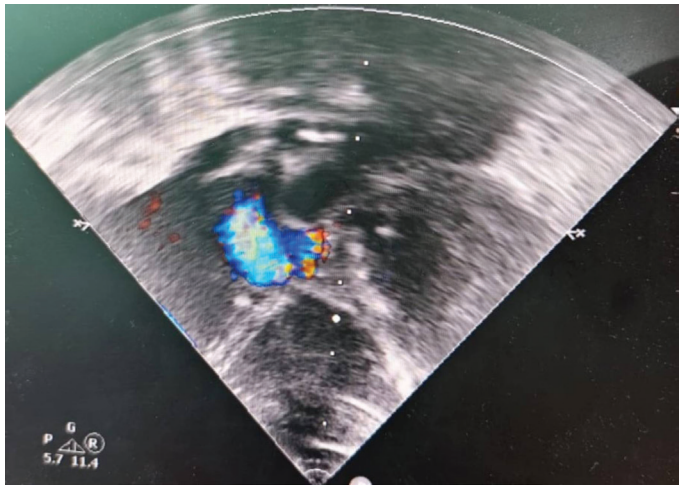

Figure 1. Preoperative echocardiography demonstrating pulmonary atresia with intact ventricular septum, secundum atrial septal defect with bidirectional shunt, patent ductus arteriosus, hypoplastic pulmonary arteries, right-sided chamber dilation with moderate tricuspid regurgitation and preserved left ventricular systolic function

Urgent surgical palliation was planned because persistently unstable oxygenation despite PGE1 infusion and non-invasive respiratory support indicated duct-dependent pulmonary blood flow. The patient was classified as ASA physical status IV; informed consent was obtained, and standard preoperative fasting was followed.

Preoperatively, the patient remained on CPAP under continuous monitoring and received premedication with intravenous atropine sulfate 0.1 mg and fentanyl 10 mcg. General anesthesia was induced with an additional 10 mcg of fentanyl and 1 mg of atracurium, and was maintained with inhaled oxygen and sevoflurane at approximately 1%. An opioid-based technique was used to maintain hemodynamic stability, with invasive arterial and central venous monitoring. Mean arterial pressure was maintained between 45-55 mmHg with a stable heart rate; central venous pressure ranged from 8 to 10 mmHg. Pressure-controlled ventilation, aimed at maintaining normocapnia with an FiO_2 of 40-50% and positive end-expiratory pressure of 4 cmH_2O, ensures balanced Qp:Qs and stable SVR while avoiding excessive drops in pulmonary vascular resistance (PVR).

The surgical procedure was performed via median sternotomy without CPB. Intraoperative observations revealed hypoplastic branch pulmonary arteries and a diminutive main pulmonary artery. A Brock procedure, which included commissurotomy and dilation of fused valve leaflets, was performed. A purse-string suture was placed near the pulmonary annulus, and transventricular perforation of the atretic pulmonary valve was then performed using a 14-gauge catheter. Subsequent dilation using a 5 mm Hegar dilator restored antegrade flow across the RV outflow tract. After restoration of antegrade pulmonary flow, oxygen saturation improved to approximately 80% at FiO_2 of 50%. Blood loss was minimal. The patient was transferred to the NICU, mechanically ventilated and receiving a dobutamine infusion (10 mcg/kg/min).

The postoperative course was hemodynamically stable. Echocardiography showed preserved left ventricular systolic function (ejection fraction 75%), moderate tricuspid regurgitation, PDA (+), and residual ASD (Figure 2). Mechanical ventilation was maintained until postoperative day 7 to allow for gradual cardiopulmonary adaptation after RV decompression. The patient was subsequently extubated and discharged on day 9 post-surgery. At outpatient follow-up, antegrade RV-PA flow remained patent, although the channel was relatively small. The patient remained under serial cardiology surveillance and was being evaluated for future staged palliation with a modified BT shunt, if required.

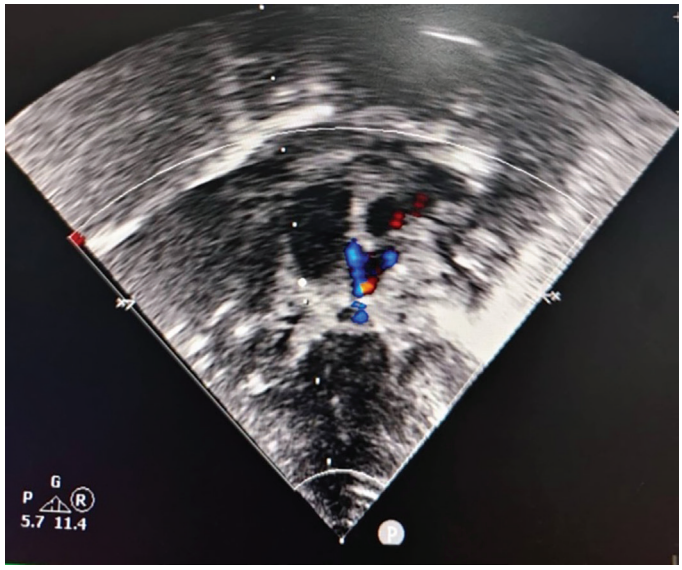

Figure 2. Postoperative echocardiography showing restored antegrade pulmonary blood flow, preserved left ventricular systolic function (ejection fraction 75%), persistent moderate tricuspid regurgitation, residual secundum atrial septal defect with bidirectional shunt and patent ductus arteriosus

DISCUSSION

PA-IVS is a complex, cyanotic congenital heart disease. The therapeutic strategy depends on RV morphology, coronary anatomy, pulmonary artery development, and institutional resources.[4] Determining the optimal initial palliation for neonates weighing less than 3 kg remains a formidable clinical challenge, as duct-dependent physiology carries risks of severe morbidity and mortality. Although the modified BT shunt is widely employed to augment pulmonary blood flow, it is associated with significant morbidity and mortality in low-birth-weight neonates. Lower body weight and complex anatomy have been associated with unfavorable early outcomes after shunt placement.[5,6]

The risk of postoperative hemodynamic instability is further amplified by a decline in PVR following shunt placement. In our 2.6 kg patient, the smallest available graft (4 mm) raised concerns about potential overshunting. Treatment selection was further influenced by local resource constraints. Ideally, pulmonary blood supply, including major aortopulmonary collateral arteries, should be evaluated by cardiac catheterization.[3,4] In resource-limited centers, inadequate pediatric cardiac intensive care and limited access to extracorporeal membrane oxygenation (ECMO) can exacerbate postoperative instability.[7] Undetected collateral flow may lead to unpredictable pulmonary overcirculation after shunt placement.[6]

Transcatheter pulmonary valvuloplasty is an alternative to RV decompression in selected patients.[8] However, surgical valvotomy remains more reliable in cases with complex anatomy or limited catheter capabilities.[9] At the time of the intervention, neonatal transcatheter procedures, hybrid procedures, and ECMO were not available, further influencing treatment decisions. In this patient, duct-dependent hemodynamic instability, uncertain pulmonary vascular anatomy, and concerns regarding shunt-related hemodynamic imbalance favored the primary Brock procedure as the initial palliative strategy. This decision was further supported by anatomical considerations, namely the presence of a tripartite RV, balanced ventricular dimensions, and preserved tricuspid annular size, all of which favored RV decompression and the potential for biventricular circulation. Furthermore, echocardiography demonstrated no evidence of major coronary sinusoids, coronary fistulae, or right-ventricle-dependent coronary circulation, thereby reducing concerns about myocardial ischemia after decompression.[2]

Although a modified BT shunt was initially considered, concerns regarding overshunting in a low-weight neonate with favorable RV morphology supported an initial decompressive strategy using the Brock procedure. Given the anatomical findings, a single-ventricle approach was not pursued as the initial strategy because these features were deemed supportive of biventricular circulation and RV decompression.[3]

Collectively, these findings support the Brock procedure as a suitable initial strategy for establishing antegrade pulmonary blood flow. This technique permits transventricular valvotomy without CPB, thereby avoiding capillary leak, coagulopathy, and inflammatory sequelae associated with CPB.[3,10] Compared with the modified BT shunt, which carries vascular, prosthetic and antithrombotic risks, the primary Brock procedure preserves native pulmonary blood flow and may simplify postoperative care.[6]

Urgent intervention was required because the neonate was dependent on continuous PGE1 infusion to maintain ductal patency. Despite pharmacological and non-invasive ventilatory support, oxygen saturation fluctuated between 50-75%, with persistent respiratory distress and metabolic acidosis, reflecting a critically limited cardiopulmonary reserve.

Nevertheless, important physiological trade-offs must be recognized following RV decompression. Sudden decompression may alter ventricular load and increase pulmonary blood flow, potentially precipitating systemic hypotension, pulmonary overcirculation, or transient ventricular dysfunction in neonates with a hypertrophied, non-compliant RV.[1,11] Restoration of antegrade pulmonary flow improved hemodynamic responsiveness during the perioperative period and permitted

modulation of the Qp:Qs balance by adjusting ventilation, SVR, and inotropic support.[1]

In this patient with a hypertrophied and relatively non-compliant RV, anesthetic management prioritized the maintenance of RV performance and coronary perfusion. Anesthetic induction was conducted gradually to avoid abrupt reductions in SVR, and ventilatory parameters were carefully titrated to prevent decreases in PVR.[2,12]

Perioperative priorities included oxygenation control, SVR maintenance, RV preload preservation, and continuous invasive hemodynamic monitoring. An opioid-based induction combined with low-dose inhalational anesthesia was selected to reduce sympathetic responses while maintaining hemodynamic stability.[1,13] Prolonged mechanical ventilation, in this case, reflected the physiological challenges associated with acute decompression of a hypertrophied and relatively non-compliant RV, including the potential for persistent diastolic dysfunction and the need for gradual hemodynamic adaptation. Mechanical ventilation was progressively weaned while maintaining adequate oxygenation and hemodynamic stability, with transition to non-invasive ventilation and then to low-flow supplemental oxygen prior to discharge. This staged approach facilitated progressive cardiopulmonary adaptation while avoiding abrupt perturbations in RV loading conditions.

Study Limitations

This report has several limitations. Formal tricuspid valve Z-score calculations and quantitative RV volume measurements were not available in the retrospective echocardiographic records. During follow-up, serial quantitative assessments of RV growth and residual pulmonary regurgitation could not be consistently obtained.

CONCLUSION

In neonates with PA-IVS, the selection of the primary Brock procedure should be guided by patient-specific anatomy and physiology, especially the presence of unstable duct-dependent circulation and the risk of shunt-related imbalance. Restoration of antegrade pulmonary blood flow enabled more physiologic perioperative regulation of Qp:Qs. In resource-limited cardiac settings, optimal outcomes depend on close multidisciplinary collaboration and careful perioperative anesthetic management to preserve systemic perfusion.

Ethics

Informed Consent: Written informed consent for publication of this case report and accompanying clinical information was obtained from the patient's parents.

Footnotes

Authorship Contributions

Surgical and Medical Practices: A., Y.W., Concept: B.I., A.H., Design: B.I., A., A.H., Data Collection or Processing: B.I., A., Y.W., Analysis or Interpretation: B.I., A., Y.W., A.H., Literature Search: B.I., Writing: B.I., A., Y.W., A.H.

Conflict of Interest: No conflict of interest was declared by the authors.

Financial Disclosure: The authors declared that this study received no financial support.

REFERENCES

1. Andropoulos DB, Mossad EB, Gottlieb EA, editors. Anesthesia for congenital heart disease. 4th ed. Hoboken (NJ): Wiley-Blackwell; 2023.
2. Gleich S, Latham GJ, Joffe D, Ross FJ. Perioperative and anesthetic considerations in pulmonary atresia with intact ventricular septum. Semin Cardiothorac Vasc Anesth. 2018;22:256-64.
3. Jonas RA. Comprehensive surgical management of congenital heart disease. 2nd ed. London: CRC Press; 2014.
4. Chikkabyrappa SM, Loomba RS, Tretter JT. Pulmonary atresia with an intact ventricular septum: preoperative physiology, imaging, and management. Semin Cardiothorac Vasc Anesth. 2018;22:245-55.
5. Sasikumar N, Hermuzi A, Fan CS, Lee KJ, Chaturvedi R, Hickey E, *et al.* Outcomes of Blalock-Taussig shunts in current era: a single center experience. Congenit Heart Dis. 2017;12:808-14.
6. Ide Y, Tachimori H, Hirata Y, Hirahara N, Ota N, Sakamoto K, *et al.* Risk analysis for patients with a functionally univentricular heart after systemic-to-pulmonary shunt placement. Eur J Cardiothorac Surg. 2021;60:377-83.
7. Murni IK, Musa NL. The need for specialized pediatric cardiac critical care training program in limited resource settings. Front Pediatr. 2018;6:59.
8. Hascoët S, Borrhomée S, Tahhan N, Petit J, Boet A, Houyel L, *et al.* Transcatheter pulmonary valvuloplasty in neonates with pulmonary atresia and intact ventricular septum. Arch Cardiovasc Dis. 2019;112:323-33.
9. Hu R, Zhang H, Dong W, Liu X, Xu Z, Liu J. Transventricular valvotomy for pulmonary atresia with intact ventricular septum in neonates: a single-centre experience in mid-term follow-up. Eur J Cardiothorac Surg. 2015;47:168-72.
10. Lawson S, Ellis C, McRobb C, Mejak B. Mechanical aspects of pediatric cardiopulmonary bypass. *In* Pediatric and Congenital Cardiology, Cardiac Surgery and Intensive Care, da Cruz EM, Ivy D, Jaggers J, (eds.). London: Springer; 2014, pp. 771-789.
11. Shaddy RE, Penny DJ, Feltes TF, Cetta F, Redington AN, editors. Moss & Adams' Heart Disease in Infants, Children, and Adolescents: Including the Fetus and Young Adult. 10th ed. Philadelphia (PA): Wolters Kluwer; 2022.
12. Arora RC, Brown JK, Chatterjee S, Gan TJ, Singh G, Tong MZ. Perioperative management of the vulnerable and failing right ventricle. Perioper Med. 2024;13:40.
13. Junghare SW, Desurkar V. Congenital heart diseases and anaesthesia. Indian J Anaesth. 2017;61:744-52.