





DOI: 10.4274/ijca.2024.96168

Int J Cardiovasc Acad 2025;11(1):34-37

Persistent False-Positive Troponin I Elevation Due to Heterophile Antibody Interference: A Case Report

 Sinan Akıncı¹,  Serap Arıkan²,  Ertan Akbay¹,  Adem Adar¹

¹Department of Cardiology, Başkent University Faculty of Medicine Alanya Application and Research Center, Antalya, Türkiye

²Department of Biochemistry, Başkent University Faculty of Medicine Alanya Application and Research Center, Antalya, Türkiye

Abstract

Troponins are important biomarkers in the diagnosis of acute coronary syndrome (ACS). In this case report, we present the clinical course of an 80-year-old female patient who presented with complaints of fever, sore throat, and fatigue. Although the patient was initially diagnosed with non-ST elevation myocardial infarction and coronavirus disease-2019 infection, detailed examinations revealed that elevated troponin I levels were due to heterophile antibodies and that the diagnosis of ACS was excluded. It was understood that the consistently elevated troponin I levels in the patient, who had previously undergone coronary angiography and long-term dual antiplatelet therapy with a diagnosis of ACS, were due to the presence of these antibodies. This case report demonstrates that clinicians should be aware of potential false-positive troponin results due to heterophile antibodies, particularly in patients with persistently elevated troponin levels without typical clinical and diagnostic findings.

Keywords: Acute coronary syndrome, troponins, heterophile antibodies

INTRODUCTION

Troponins are essential biomarkers for diagnosing acute coronary syndromes (ACS) and assessing myocardial injury.^[1] The interpretation of troponin levels can be complicated by various factors, including heterophile antibodies.^[2] These antibodies can cross-react with assay components, potentially leading to false-positive results that may misguide clinical decisions.^[3] We present a case of a patient suspected of having ACS, whose elevated troponin I levels were erroneously attributed to heterophile antibody interference. This case emphasizes the importance of considering alternative explanations for elevated troponin levels and highlights the need for clinicians to recognize potential assay interferences. Our report aims to raise awareness about heterophile antibody interference in troponin testing and promote careful interpretation of results.

CASE REPORT

An 80-year-old woman came to the emergency department with complaints of fever, sore throat, and fatigue lasting two days. She did not report chest pain or difficulty in breathing. She had a history of hypertension and coronary artery disease. She underwent coronary angiography for ACS 6 years, and 1 year ago, both of which revealed no significant stenosis, aside from the presence of coronary plaques. Her daily medications included acetylsalicylic acid (100 mg), clopidogrel (75 mg), metoprolol (50 mg), atorvastatin (20 mg), and amlodipine/valsartan (5/160 mg).

On admission, her blood pressure was 130/80 mmHg, heart rate was 86 bpm, body temperature was 38.1 °C, and oxygen saturation was 92% on room air. Physical examination showed

To cite this article: Akıncı S, Arıkan S, Akbay E, Adar A. Persistent false-positive troponin I elevation due to heterophile antibody interference: a case report. Int J Cardiovasc Acad. 2025;11(1):34-37



Address for Correspondence: Assoc. Prof. Sinan Akıncı, Department of Cardiology, Başkent University Faculty of Medicine Alanya Application and Research Center, Antalya, Türkiye
E-mail: akincisinan@gmail.com
ORCID ID: orcid.org/0000-0001-5250-5404

Received: 05.11.2024
Accepted: 24.12.2024
Epub: 11.03.2025
Publication Date: 18.03.2025



©Copyright 2025 by the Cardiovascular Academy Society / International Journal of the Cardiovascular Academy published by Galenos Publishing House.
 Licenced by Creative Commons Attribution-NonCommercial-NoDerivatives 4.0 (CC BY-NC-ND 4.0)

oropharyngeal hyperemia, but cardiac and pulmonary examinations were normal. Laboratory tests revealed an elevated C-reactive protein level of 38.3 mg/dL and a slightly elevated D-dimer level of 604.5 mg/L, while other biochemical parameters were within normal limits. The complete blood count revealed neutrophil predominance (Table 1). The patient tested positive for coronavirus disease-2019 (COVID-19) antigen, and troponin I levels [ARCHITECT STAT assay, abbot laboratories, Illinois, United States of America (USA)] were markedly elevated at 37,430 ng/L (reference range: 0-16 ng/L). Based on these findings, we initially diagnosed non-ST elevation myocardial infarction (NSTEMI) and COVID-19 infection and admitted the patient to the intensive care unit.

Despite the marked troponin I elevation, the electrocardiogram (ECG) remained normal (Figure 1), and transthoracic echocardiography revealed only mild left ventricular hypertrophy with preserved systolic function. In the absence of ischemic symptoms, we did not proceed with early invasive intervention. Treatment consisted of enoxaparin (60 mg subcutaneously, twice daily) and molnupiravir (800 mg, twice daily), in addition to her regular medications. Throughout hospitalization, there was no progression of COVID-19 symptoms or cardiac findings.

Serial troponin I measurements remained consistently elevated (37,430 ng/L, 33,052 ng/L, 31,876 ng/L, and 33,183 ng/L), similar to levels documented during her previous ACS

admission one year earlier (Figure 2). The absence of dynamic troponin changes, typical ischemic findings on ECG, and echocardiography, or other clinical evidence of ACS, prompted us to suspect a false-positive result. A subsequent troponin T assay yielded <10 ng/L (reference range: 0-14 ng/L). Testing troponin I in a heterophile antibody-blocking tube (Scantibodies Laboratory, CA, USA) produced a significantly

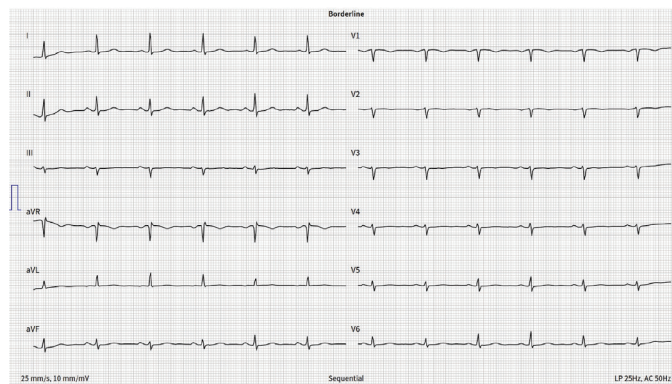


Figure 1: Patient’s baseline electrocardiogram

Table 1: Patient laboratory results at admission

Hematology	Result	Reference range
Hemoglobin (g/dL)	15.4	12-16.5
WBC (×10 ³ /mL)	9.66	4.5-11
Platelets (×10 ³ /mL)	207	140-440
Neutrophils (%)	74	40-72
Lymphocytes (%)	13	20-47
Chemistry		
Glucose (mg/dL)	82	80-110
Creatinine (mg/dL)	0.86	0.5-1.2
Sodium (mmol/L)	141	132-145
Potassium (mmol/L)	3.89	3.5-5.5
AST (U/L)	20	5-35
HDL cholesterol (mg/dL)	57	40-80
LDL cholesterol (mg/dL)	120	60-130
Triglycerides (mg/dL)	96	55-150
CRP (mg/L)	38.8	0-5
Creatine kinase (U/L)	40	<168
D-dimer (mg/L)	604.5	<500
Troponin I (ng/L)	37430.5	0-16

WBC: White blood cells, HDL: High-density lipoprotein, LDL: Low-density lipoprotein, CRP: C-reactive protein, AST: Aspartate aminotransferase

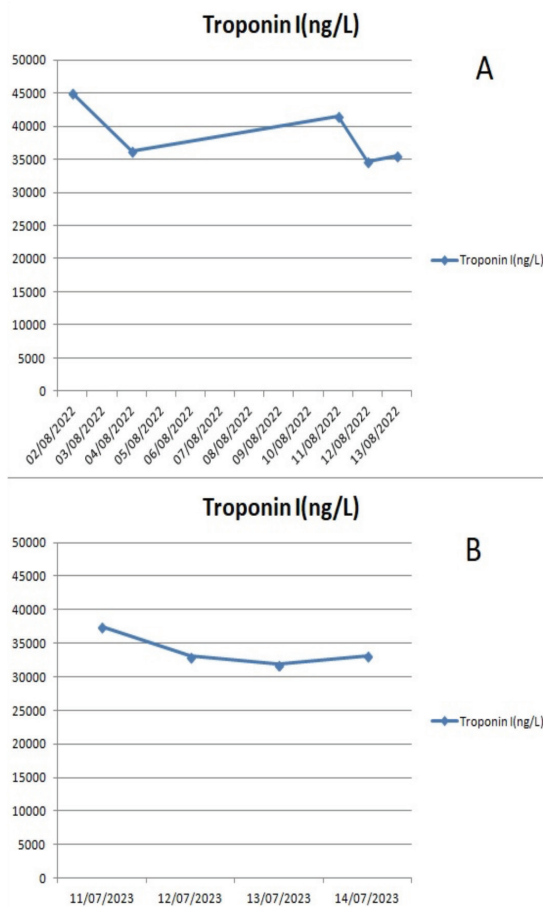


Figure 2: Graph of the patients troponin levels. (A) Hospitalization one year ago; (B) Current hospitalization

lower value of 62 ng/L, confirming heterophile antibody interference. This finding led us to exclude ACS. We discharged the patient with stable COVID-19 status, discontinued clopidogrel, and maintained her other medications. One-year follow-up demonstrated continued stability. Informed consent was obtained.

DISCUSSION

Cardiac troponins have become the preferred biomarkers for diagnosing acute myocardial infarction and levels above the 99th percentile of a healthy reference population are considered diagnostic for myocardial infarction.^[4] Even small elevations in troponins correlate with higher risk of death and recurrent ischemic events in ACS patients. Patients with elevated troponins benefit most from more intensive medical therapy and early invasive management. On the other hand, troponins do not discriminate between ischemic and non-ischemic causes of myocardial injury and the clinical presentation is crucial.^[4]

Although troponins are highly specific for myocardial necrosis, false positive elevations can occur in various clinical conditions other than ACS. Renal failure, myocarditis, cardiomyopathy, pulmonary embolism, sepsis, stroke, and other critical illnesses can cause troponin elevation.^[5,6] In one study, 41% of patients with elevated troponin T did not have ACS, and the positive predictive value was only 56%.^[7]

Elevated troponin levels are commonly observed in patients with COVID-19 infection, with studies reporting that up to 45% of hospitalized patients have elevated troponin levels.^[8] This elevation may be due to several factors, including myocardial injury, myocarditis, stress cardiomyopathy, or supply-demand mismatch. In this case, the patient's troponin levels were initially thought to be indicative of NSTEMI, leading to her admission to the intensive care unit and initiation of appropriate treatment. In the follow-up, it was determined that the elevated troponin levels were not genuine but were caused by test interference due to heterophile antibodies. Consequently, troponin elevation related to COVID-19 infection was ruled out. Although there are reports in the literature of falsely elevated test results for substances such as D-dimer in COVID-19 patients due to heterophile antibodies, no such data exist regarding troponin.^[9] Furthermore, it remains unclear whether the heterophile antibodies observed in these cases are associated with COVID-19 infection. In our case, we observed similarly elevated troponin levels a year prior, leading us to conclude that the heterophile antibodies were not related to COVID-19 infection.

Heterophile antibodies are an under-recognized cause of false-positive troponin results. These antibodies can interfere with immunoassays like troponin tests, and cause false positive results. The prevalence of false-positive troponin elevations

due to heterophile antibodies is estimated to be around 0.17-3.1%. In one study, 15% of troponin elevations in rheumatoid factor-positive subjects were found to be false positives.^[10] The antibodies can bind to the assay reagents and lead to a potentially high troponin result not reflective of actual myocardial injury.

False-positive troponin results caused by heterophile antibodies can lead to unnecessary diagnostic procedures and treatments, as seen in this patient, who underwent coronary angiography twice and received dual antiplatelet therapy for an extended period. When interference is suspected, the laboratory can use blocking reagents, test with a different assay, or look for characteristic dynamics of troponin rise and fall to address the issue.^[11] In this case, the patient's initial troponin I values were found to be consistently elevated, even when she was admitted with ACS a year ago. The absence of typical ECG and echocardiographic findings, as well as the lack of progression in COVID-19 symptoms, raised suspicion of a false-positive troponin result. Further testing with a troponin T assay and a heterophilic antibody blocking tube confirmed the presence of heterophilic antibodies, leading to the exclusion of ACS as the primary diagnosis.

In this case, although we demonstrated that there was no actual myocardial injury using troponin T levels, cardiac magnetic resonance imaging (MRI), could have provided additional insights by assessing myocardial damage and COVID-19 involvement. In similar cases, cardiac MRI may offer additional information about the condition. Furthermore, the presence of heterophile antibodies was identified using heterophile blocking tubes and alternative tests. Methods such as serial dilution could also have been employed as alternative approaches.

This case emphasizes the importance of correlating laboratory findings with the clinical presentation and other diagnostic tests. While elevated troponin levels are commonly associated with myocardial injury, it is essential to consider other potential causes, such as heterophilic antibodies, which can lead to false-positive results.

Ethics

Informed Consent: Informed consent was obtained.

Footnotes

Authorship Contributions

Surgical and Medical Practices: S.A., S.Ar., E.A., A.A., Data Collection or Processing: S.A., S.Ar., Analysis or Interpretation: S.A., S.Ar., E.A., A.A., Literature Search: S.A., E.A., A.A., Writing: S.A., E.A., A.A.

Conflict of Interest: No conflict of interest was declared by the authors.

Financial Disclosure: The authors declared that this study received no financial support.

REFERENCES

1. Collet JP, Thiele H, Barbato E, Barthélémy O, Bauersachs J, Bhatt DL, *et al.* 2020 ESC Guidelines for the management of acute coronary syndromes in patients presenting without persistent ST-segment elevation. *Eur Heart J.* 2021;42:1289-367.
2. Chaulin AM. False-Positive Causes in Serum Cardiac Troponin Levels. *J Clin Med Res.* 2022;14:80-7.
3. Lakusic N, Sopek Merkas I, Lucinger D, Mahovic D. Heterophile antibodies, false-positive troponin, and acute coronary syndrome: a case report indicating a pitfall in clinical practice. *Eur Heart J Case Rep.* 2021;5:ytab018.
4. Thygesen K, Alpert JS, Jaffe AS, Chaitman BR, Bax JJ, Morrow DA, *et al.* Fourth Universal Definition of Myocardial Infarction (2018). *J Am Coll Cardiol.* 2018;72:2231-64.
5. Giannitsis E, Katus HA. Cardiac troponin level elevations not related to acute coronary syndromes. *Nat Rev Cardiol.* 2013;10:623-34.
6. Zaki HA, Shaban AE, Shaban AE, Shaban EE. Interpretation of cardiac and non-cardiac causes of elevated troponin T levels in non-acute coronary syndrome patients in the emergency department. *Cureus.* 2022;14:e22703.
7. Alcalai R, Planer D, Culhaoglu A, Osman A, Pollak A, Lotan C. Acute coronary syndrome vs nonspecific troponin elevation: clinical predictors and survival analysis. *Arch Intern Med.* 2007;167:276-81.
8. De Michieli L, Jaffe AS, Sandoval Y. Use and prognostic implications of cardiac troponin in COVID-19. *Heart Fail Clin.* 2023;19:163-76.
9. Ozbalci D, Doguc DK, Yilmaz G, Ozturk O, Sirin FB, Akcam FZ. Interference of D-dimer levels from heterophilic antibody in COVID-19: a serious concern in treatment and follow-up of patients. *Int J Lab Hematol.* 2022;44:e13-6.
10. Krahn J, Parry DM, Leroux M, Dalton J. High percentage of false positive cardiac troponin I results in patients with rheumatoid factor. *Clin Biochem.* 1999;32:477-80.
11. Lippi G, Aloe R, Meschi T, Borghi L, Cervellin G. Interference from heterophilic antibodies in troponin testing. Case report and systematic review of the literature. *Clin Chim Acta.* 2013;426:79-84.